

Isolated renal and urinary tract aspergillosis: a systematic review

Felix Bongomin , Bethan Morgan, Bassey E. Ekeng, Martha F. Mushi, Winnie Kibone, Ronald Olum, David B. Meya, Davidson H. Hamer and David W. Denning

Ther Adv Urol

2023, Vol. 15: 1–18

DOI: 10.1177/
17562872231218621

© The Author(s), 2023.
Article reuse guidelines:
sagepub.com/journals-
permissions

Abstract

Background: Aspergillosis localized to the kidneys and the urinary tract is uncommon. We conducted a comprehensive systematic review to evaluate risk factors and clinical outcomes of patients with isolated renal and genito-urinary tract aspergillosis.

Methods: We systematically searched Medline, CINAHL, Embase, African Journal Online, Google Scholar, and the Cochrane Library, covering the period from inception to August 2023 using the key terms 'renal' OR 'kidney*' OR 'prostate' OR 'urinary bladder' OR 'urinary tract*AND 'aspergillosis' OR 'aspergillus' OR 'aspergilloma' OR 'mycetoma'. We included single case reports or case series. Review articles, guidelines, meta-analyses, animal studies, protocols, and cases of genitourinary and /or renal aspergillosis occurring as a part of disseminated disease were excluded.

Results: We identified 91 renal and urinary aspergillosis cases extracted from 76 publications spanning 1925–2023. Among the participants, 79 (86.8%) were male, with a median age of 46 years. Predominantly, presentations consisted of isolated renal infections (74 instances, 81.3%), followed by prostate (5 cases, 5.5%), and bladder (7 cases, 7.7%) involvement. *Aspergillus fumigatus* (42.9%), *Aspergillus flavus* (9.9%), and *Aspergillus niger/glaucus* (1.1% each) were isolated. Underlying risk factors included diabetes mellitus (29.7%), HIV (12.1%), haematological malignancies (11%), and liver cirrhosis (8.8%), while common symptoms encompassed flank pain (36.3%), fever (33%), and lower urinary tract symptoms (20.9%). An autopsy was conducted in 8.8% of cases. Diagnostic work-up involved histopathology (70.5%), renal CT scans and urine microscopy and culture (52.6% each), and abdominal ultrasound (17.9%). Treatments included amphotericin B (34 cases, 37.4%) and azole-based regimens (29 cases, 31.9%). Nephrectomy was performed in 16 of 78 renal cases (20.5%). All-cause mortality was 24.4% (19 cases). No significant mortality rate difference was observed among antifungal regimens ($p=0.739$) or nephrectomy status ($p=0.8$).

Conclusion: Renal and urinary aspergillosis is an important cause of morbidity and mortality, particularly in immunocompromised and people with diabetes mellitus. While varied treatment strategies were observed, mortality rates showed no significant differences based on treatments or nephrectomy status. Further research is needed to refine diagnostics, optimize treatments, and enhance awareness among clinicians for early detection and management.

PROSPERO registration number: CRD42023430959.

Correspondence to:

Felix Bongomin
Department of Medical
Microbiology and
Immunology, Faculty of
Medicine, Gulu University,
Gulu, Uganda

Manchester Fungal
Infection Group, Division
of Evolution, Infection
and Genomics, Faculty
of Biology, Medicine and
Health, University of
Manchester, Manchester,
UK

drbongomin@gmail.com

Bethan Morgan
Trust Library Services,
Wythenshawe Hospital,
Manchester University
NHS Foundation Trust,
Manchester, UK

Bassey E. Ekeng
Department of Medical
Microbiology and
Parasitology, University of
Calabar Teaching Hospital,
Calabar, Nigeria

Martha F. Mushi
Department of
Microbiology and
Immunology, Weill
Bugando School of
Medicine, Catholic
University of Health and
Allied Sciences, Mwanza,
Tanzania

Winnie Kibone
Department of Medical
Microbiology and
Immunology, Faculty of
Medicine, Gulu University,
Gulu, Uganda

Ronald Olum
School of Public Health,
College of Health
Sciences, Makerere
University, Kampala,
Uganda

David B. Meya

Infectious Diseases
Institute, Department
of Medicine, College of
Health Sciences, Makerere
University, Kampala,
Uganda

Davidson H. Hamer

Department of Global
Health, Boston University
School of Public Health,
Boston, MA, USA

Section of Infectious
Diseases, Boston
University Chobanian
& Avedisian School of
Medicine, Boston, MA, USA

National Emerging
Infectious Disease
Laboratory, Boston, MA,
USA

Center for Emerging
Infectious Diseases Policy
& Research, Boston
University, Boston, MA,
USA

David W. Denning

Manchester Fungal
Infection Group, Division
of Evolution, Infection
and Genomics, Faculty
of Biology, Medicine and
Health, University of
Manchester, Manchester,
UK

Plain language summary

What you need to know now about kidney and urinary tract infections caused by the fungus aspergillus

In this study, we investigated the rare occurrence of aspergillosis, a fungal infection caused by the mold *Aspergillus*, specifically affecting the kidneys and urinary tract (ureters, urinary bladder, prostate and urethra). This disease was first described in 1891 in Germany. To update our current understanding of this rare disease, we conducted a thorough review, examining risk factors and outcomes for individuals with *Aspergillus* infection of the kidney and/or urinary tract. We found 91 cases from 76 published articles spanning nearly a century, identifying common features such as predominantly male patients (almost every 9 in 10 cases) and isolated infection of one or both kidneys being the most common (8 in 10 cases). Diabetes mellitus, HIV infection, and certain cancers were noted as underlying risk factors, with symptoms ranging from flank pain, passing of blood in urine, passing of fungal particles (bezoars) in urine, pain while passing urine to fever. Diagnostic methods included histopathology and imaging techniques, while treatments varied, involving antifungal medications such as voriconazole and amphotericin B, drainage of abscesses, and, in some cases, surgical removal of the affected kidney (nephrectomy). Overall, about 1 in every 4 of the affected people died. Despite diverse treatment approaches, the study found no significant difference in mortality rates, emphasizing the need for further research to improve diagnostics, refine treatments, and raise awareness for early detection and management, especially among immunocompromised individuals such as those with diabetes mellitus and HIV infection.

Keywords: clinical presentation, genito-urinary tract, isolated renal aspergillosis, risk factors, treatment outcomes

Received: 12 September 2023; revised manuscript accepted: 16 November 2023.

Introduction

Aspergillosis, caused by several species of the opportunistic fungal pathogen within the *Aspergillus* genus, primarily manifests as a pulmonary disease; however, instances of extra-pulmonary dissemination and localized diseases are well described.^{1–3} Findings from autopsy studies show that extra-pulmonary aspergillosis, involving the heart, kidney, central nervous system, gastrointestinal tract, spleen, liver, thyroid gland and pancreas, occurs in over 50% of cases of invasive aspergillosis.^{4,5}

Renal and urinary tract aspergillosis is an infrequent yet potentially severe fungal infection that affects the genital urinary system, posing significant clinical challenges, particularly in individuals with notable immunosuppression.⁶ While the kidneys are the organs most frequently affected, there have been occasional instances of involvement of the urinary bladder, prostate, ureters,

and urethra.^{7–10} In autopsy series of HIV decedents, kidney involvement was documented in about 15% of fatal cases of invasive aspergillosis.¹¹ Infections in the urinary tract can arise from haematogenous spread originating from disseminated aspergillosis or contiguous spread from adjacent organs, such as an intra-abdominal source.⁶ In experimental murine aspergillosis, infected intravenously, the kidneys carry the highest burden of infection.^{12,13} However, isolated cases of renal and urinary aspergillosis occurring in patients without evidence of systemic dissemination has been documented,^{14,15} and one case acquired peri-operatively.¹⁶

Much as isolated renal aspergillosis can occur in apparently immunocompetent individuals,¹⁷ important risk factors for isolated renal aspergillosis include genito-urinary instrumentation, HIV/AIDS, solid organ transplantation, haematological malignancies and bone marrow transplantation,

and other forms of immunosuppression.^{18–20} Diagnosis of genito-urinary aspergillosis is often challenging as symptoms such as flank pain, urinary tract obstruction, haematuria, and constitutional symptoms are non-specific in terms of the underlying aetiological agent.²¹ Medical imaging, diagnostic autopsies, and histopathological examination of biopsy specimens are required for definitive diagnosis.^{5,18,22}

A fundamental challenge in therapy is that none of the available antifungal agents with activity against *Aspergillus* spp. penetrate the urine, although they do get into renal, bladder and prostate tissue.²³ A combination of surgical and medical therapies, including nephrectomy and prostatectomy, with or without systemic antifungal treatment, has been employed to treat renal and genitourinary tract aspergillosis, resulting in varying outcomes.^{24–26} The objective of this systematic review was to comprehensively analyse documented cases of isolated renal and genitourinary tract aspergillosis, aiming to investigate the clinical presentation, risk factors, diagnosis, management, and clinical outcomes of patients affected by this relatively uncommon form of aspergillosis.

Methods

Protocol and registration

This systematic review was conducted following the preferred reporting items for systematic review and meta-analysis (PRISMA) guidelines²⁷ and the study protocol was prospectively registered with PROSPERO (Registration number: CRD42023430959).

Eligibility criteria

The inclusion criteria consisted of articles describing histologically proven or culture-confirmed cases of isolated renal and/or genitourinary tract aspergillosis involving adults or children following the PEO (Population, Exposure, Outcome) criteria outlined in Table 1.

Database search

A qualified medical librarian (BM) systematically conducted searches across numerous databases, including Medline, CINAHL, EMBASE, African Journal Online, Google Scholar, and the Cochrane Library, covering the period from inception to

Table 1. The population, exposure, and outcome criteria.

Criteria	Component
Population	Children and adults with isolated renal and or genito-urinary tract aspergillosis
Exposure	<ol style="list-style-type: none"> 1. Antifungal therapy 2. Surgical interventions 3. Underlying co-morbidities 4. Genito-urinary instrumentations and procedures 5. Organ transplantation
Outcome	<ol style="list-style-type: none"> 1. Resolution of symptoms 2. Survival 3. Morbidity

August 2023. The Medical Subject Headings (MeSH) terms and keywords ‘renal’ OR ‘kidney*’ OR ‘prostate’ OR ‘bladder’ OR ‘urinary tract*’

AND ‘aspergillosis’ OR ‘aspergillus’ OR ‘aspergilloma’ OR ‘mycetoma’, and [Aspergillosis AND (renal OR kidney* OR urinary tract* OR bladder OR prostate)] were used. Furthermore, a manual examination of references from all citations meeting our study’s inclusion criteria was carried out. The search results were exported and processed through RefWorks to eliminate duplicate research articles.

Inclusion and exclusion criteria

We included single case reports or case series. Review articles, guidelines, meta-analyses, animal studies, environmental studies, protocols, and cases of genitourinary and/or renal aspergillosis occurring as a part of disseminated disease were excluded.

Data screening and extraction

Four authors (BM, BEE, MFM, WK) conducted independent assessments of search outcomes to establish eligibility by screening titles and abstracts. Retrieval of pertinent full-text articles was undertaken. Additionally, scrutiny of the bibliographies from the search findings was performed. We systematically eliminated duplicated and repetitive findings, non-English articles, as well as reports with inadequate patient information. English-language articles that encompassed essential patient particulars were selected through a meticulous process. Any disagreements regarding inclusion were resolved through a collaborative

consensus. FB undertook a comprehensive review and provided ultimate endorsement for all the included papers.

Two sets of independent reviewers extracted data (BM and BEE, and MFM and WK), which was subsequently coded. We used a data extraction form prepared using Microsoft Excel 2016 to collect information from all eligible studies such as year of publication, first author's name, number of cases, method of diagnosis, aspergillus species, autopsy, antifungal agents used and duration, and clinical outcomes (survived or died). FB independently reviewed the extracted data, and any disagreements were resolved by consensus.

Risk of bias assessment

All included studies were either single case reports or case series including less than 10 participants and hence were not eligible for risk of bias of assessment since these studies are considered anecdotal evidence and are often included in systematic reviews to provide insights, generate hypotheses, or to illustrate clinical observations rather than drawing definitive conclusions about treatment effects.

Statistical analysis and data synthesis

Patient demographic data, clinical manifestations, underlying comorbidities, diagnostic procedures, antifungal treatment modalities employed, treatment duration, and clinical outcomes were meticulously scrutinized and recorded within Microsoft Excel spreadsheets. Descriptive statistical analyses, encompassing measures of central tendency such as mean, median, and range, were employed to present the variables and resultant outcomes. A chi-square test was conducted to compare clinical outcomes across treatment regimens and nephrectomy status among patients with renal aspergillosis. No meta-analysis was conducted, given that data pooling was not warranted.

Ethics statement

No ethical approval was required for this study as the underlying data were retrieved from publicly available sources.

Results

Search results

From the literature search, 2112 articles were identified from different sources. Of the total articles, 801 duplicate articles were excluded using RefWorks and manual tracing. The remaining 1311 articles were screened by reading their titles and abstracts; 1126 articles were excluded. Of the 185 studies sought for retrieval, 10 articles were not accessible in full text, and 175 articles were screened for full-text assessment. Finally, 99 articles were excluded for various reasons and 76 articles were included in the synthesis and analysis, Figure 1.

Patient demographics and comorbidities

In total, our study encompassed 76 publications spanning from 1925 to 2023, which collectively involved 91 patients, with 79 (86.8%) of them being males. The median age of all participants was 46 years, (range: <1 month to 79 years). Fifty-four (59.3%) of the cases were aged 40 years or older.

The data were sourced from 27 different countries, with most cases originating from India ($n=32$, 35.2%), USA ($n=16$ cases, 17.6%), Spain ($n=5$, 5.5%), Turkey ($n=4$, 4.4%), and three cases (3.3%) each from Brazil and France (Figure 2).

Spectrum of renal and genito-urinary aspergillosis

Most cases involved isolated renal presentations, accounting for 74 instances (81.3%). Prostate involvement was observed in five cases (5.5%), and bladder involvement was noted in seven cases (7.7%). One case (1.1%) demonstrated a combination of renal and bladder involvement, and three cases (3.3%) presented with both renal and prostate involvement. Additionally, a single case (1.1%) was associated with only the ureter.

Among the 78 renal cases, 32 had specifications on involvement; bilateral involvement was observed in 20 cases (25.6%), left kidney involvement in 8 cases (10.3%), and right kidney involvement in 4 cases (5.1%), with specific pathologies including abscesses in 15 (19.2%) cases, aspergillomas in 10 (12.8%) cases, pyelonephritis in 1 (1.3%), and papillary necrosis in 1 (1.3%), Table 2.

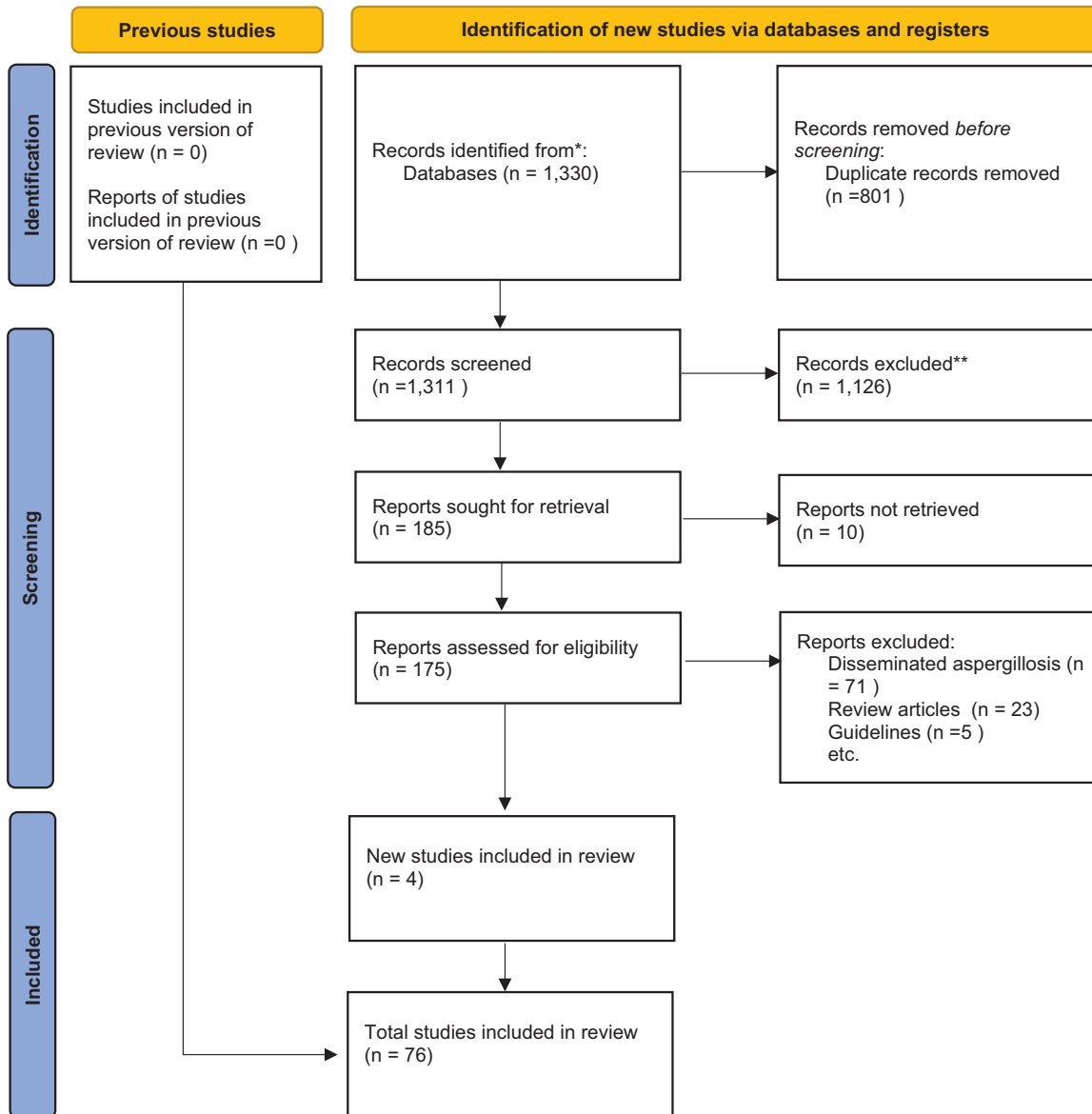


Figure 1. Preferred reporting items for systematic review and meta-analysis flow diagram.

Underlying risk factors

Nineteen cases (21%) had no reported underlying conditions whereas 27 cases (29.7%) had diabetes mellitus, 11 cases (12.1%) were associated with HIV, 10 cases (11%) were linked to haematological malignancies, 8 cases (8.8%) involved liver cirrhosis, and 5 cases (5.5%) each were related to renal transplant and injection drug use, Table 2.

Clinical presentation

The cases exhibited a range of symptoms, including 10 (11%) being asymptomatic, 33 (36.3%)

experiencing flank pain, 30 (33%) presenting with fever, 19 (20.9%) showing lower urinary tract symptoms (LUTS), 14 (15.4%) having haematuria, 14 (15.4%) displaying particles in urine (fungal balls or bezoars), and 7 (7.7%) presenting with other systemic symptoms such as weight loss and fatigue.

Diagnosis

Among the 91 cases, 41 individuals (45.1%) exhibited histopathological evidence of *Aspergillus* infection, yet the specific species remained unidentified. Of the 50 cases where species

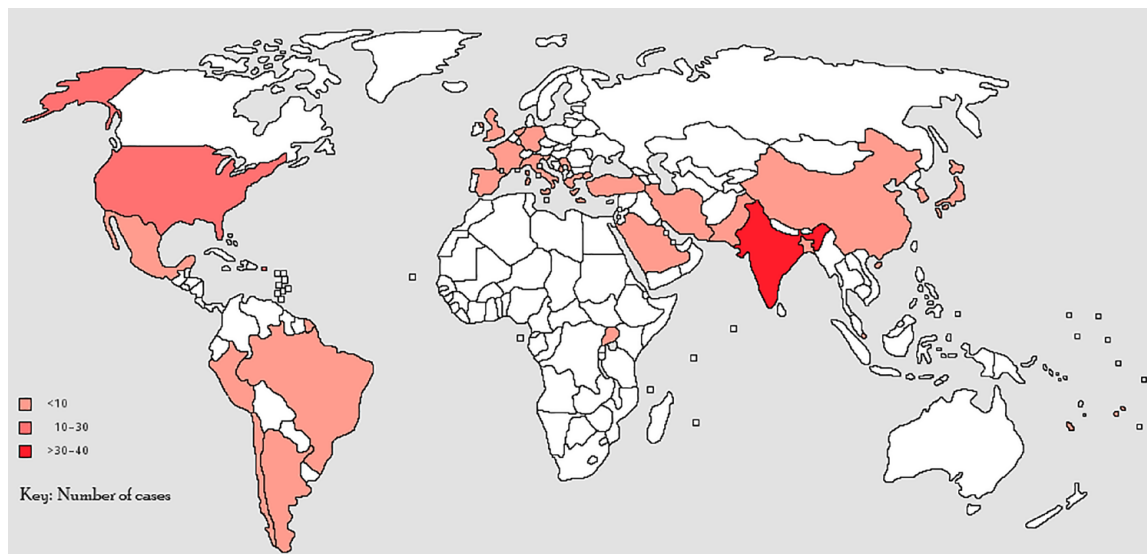


Figure 2. Distribution of isolated renal and genito-urinary tract aspergillosis cases reported across the globe.

identification was achieved, 39 (42.9%) were identified as *Aspergillus fumigatus*, 9 (9.9%) as *Aspergillus flavus*, and 1 (1.1%) each as *Aspergillus niger* and *Aspergillus glaucus*. Autopsy procedures were conducted on eight participants, representing 8.8% of the study population. Of the 78 cases of renal aspergillosis, diagnoses were mostly established through a combination of diagnostic methods. However, details of diagnostic workups were not provided for 5 cases. Histopathology of biopsy or autopsy samples was the primary diagnostic method for 55 cases (70.5%). This was followed by renal CT scans and urine microscopy and culture (MCS), both utilized in 41 cases (52.6%). Abdominal ultrasound was utilized in 14 cases (17.9%), while MRI or PET scans were used in 3 cases (3.8%). Galactomannan antigen tests were conducted in 4 cases (5.1%), Table 2.

Treatment

Sixty-three cases received antifungal therapy, with 34 (37.4%) individuals receiving amphotericin B-based treatment. This included cases where amphotericin B alone was administered (11 cases), in combination or followed by itraconazole (9 cases), and voriconazole (7 cases). In addition, flucytosine (5FC) was given in three cases, and 1 case each received amphotericin B with caspofungin and posaconazole, or isavuconazole and anidulafungin, or itraconazole and fluconazole.

Furthermore, 29 (31.9%) patients were treated with azole-based regimens, primarily voriconazole

alone ($n=16$) or in combination with caspofungin ($n=3$). Other cases involved itraconazole alone ($n=6$), in combination with voriconazole ($n=1$), or 5FC ($n=1$). Single instances of treatment with isavuconazole or caspofungin were also observed. The duration of treatment varied widely, ranging from as short as 1 week to 18 months. The treatment was not stated for 20 (22%) cases, and 7 (7.7%) cases received no antifungal treatment.

In terms of surgical procedures, a total of 19 patients underwent surgery. Among the cases of renal aspergillosis, 16 out of 78 (20.5%) underwent nephrectomy. Additionally, 2 of 8 (25%) cases involving the prostate underwent prostatectomy, while 1 of 8 (12.5%) cases concerning the bladder underwent radical cystectomy. A total of 13 (22.8%) of 57 patients with available surgical and antifungal therapy status were managed with both nephrectomy and antifungal therapy, Table 2.

Clinical outcomes

A total of 78 patients had documented clinical outcomes, including 19 (24.4%) fatalities, all linked to renal aspergillosis, Table 2. Thus, of the 67 isolated renal aspergillosis cases, mortality was 28.4% (19/67). Among the 19 fatal cases who died, 10 patients had received amphotericin B-based regimens, 2 received itraconazole, 1 was treated with a combination of voriconazole and caspofungin, 2 had no antifungal treatment, and 4 cases remained unspecified.

Table 2. Study characteristics, demographic, clinical characteristics, management, and outcomes of included classes.

S/N	Author/Year	Country	Year	Age	Sex	Diagnosis	Autopsy	Risk factor	Symptoms	Aetiology	Diagnostics	Antifungal	Surgery	Outcome	Follow-up
1	Wan et al. ²⁸	UK	2023	68	M	Renal	Yes	DM, HTN	Hx	<i>A. flavus</i>	CT, US, histopath, MCS, BDG, GM	Vori/Caspo	No	Died	NS
2	Tosh et al. ²⁹	India	2023	25	M	Renal-B	No	None	Not specified	<i>Asp</i> spp.	CT, histopath	Vori	Nephrectomy	Survived	NS
3	Paul et al. ³⁰	India	2013	34	M	Renal	No	None	Asymptomatic	<i>A. flavus</i>	Urine MCS, US, IVP, histopath, PET	Vori	Nephrectomy	Survived	NS
4	Martinez-Salas et al. ³¹	Mexico	2022	74	M	Bladder	No	BPH	Hx, incontinence, freq.	<i>Asp</i> spp.	Urine MCS, US, CT, cystoscopy, histopath	Isavu	No	Survived	NS
6	Toledo et al. ³²	Brazil	2023	62	F	Renal and Bladder	No	DM, HTN, SLE	Dysuria, FP, F	<i>Asp</i> spp.	CT, urine MCS	NS	No	Survived	NS
7	Mahdavi et al. ³³	Iran	2021	14	M	Renal-L	No	CHF	Dysuria, fatigue, anorexia	<i>A. fumigatus</i>	ESR, CRP, Urine MCS, US, MRI, CT, histopath	Vori/Caspo	No	Survived	60 months
8	Maquera-Alfaro et al. ¹⁵	Peru	2022		M	Renal-B	No	None	Not specified	<i>Asp</i> spp.	US, CT, MCS	Vori	No	Survived	NS
9	Khilar et al. ³⁴	India	2021	60	M	Renal	No	None	Not specified	<i>A. fumigatus</i>	Urine MCS, US, IVP, histopath, PET	Itra	Nephrectomy	Survived	NS
10	Karaisz et al. ³⁵	USA	2020	64	F	Renal	No	LTx	Not specified	<i>A. fumigatus</i>	CT, histopath	AMB/Isavu/Anidu	Nephrectomy	Died	NS
11	Flores-Lovon et al. ³⁶	Peru	2020	35	M	Renal	No	AIDS	Not specified	<i>A. fumigatus</i>	CT, Histopathology	NS	NS	NS	NS
12	Altinkaynak et al. ³⁷	Turkey	2019	54	M	Renal	No	Lymphoma	Asymptomatic	<i>Asp</i> spp.	CT, histopath	AMB	No	Survived	NS
13	Kone et al. ²⁵	India	2019	59	M	Renal	No	DM	Not specified	<i>Asp</i> spp.	Urine MCS, histopathology, CT	Vori	No	Survived	NS
			2019	67	M	Renal-B	No	DM	Not specified	<i>Asp</i> spp.	Urine MCS, histopath, CT	Vori	No	Survived	NS
			2019	72	M	Renal	No	DM	Not specified	<i>Asp</i> spp.	Urine MCS, histopath, CT	Vori	No	Survived	NS
			2019	60	M	Renal	No	DM	Not specified	<i>Asp</i> spp.	Urine MCS, histopath, CT	AMB/Vori	No	Survived	NS
			2019	55	M	Renal	No	DM	Not specified	<i>Asp</i> spp.	Urine MCS, histopath, CT	AMB/Vori	No	Survived	NS
14	Das et al. ¹⁷	India	2017	66	M	Renal-B	No	DM	F, FP, turbid urine	<i>A. fumigatus</i>	CT, urine MCS	AMB/Vori	No	Died	NS
15	Smolovic et al. ³⁸	Montenegro	2018	56	M	Renal-L	No	Liver cirrhosis	Asymptomatic	<i>A. fumigatus</i>	Urine MCS, histopath, CT, MRI	Vori	No	Survived	NS
16	Nagvekar et al. ³⁹	India	2018	12	F	Renal	No	RTx	FP, F	<i>A. fumigatus</i>	US, Histopath, MCS	AMB/Vori	No	Died	1 month
17	Sharmin et al. ²⁶	Bangladesh	2018	37	F	Renal	No	DM, HTN	Not specified	<i>Asp</i> spp.	US, Histopath	Itra/Vori	No	Survived	NS
18	Kamat et al. ⁴⁰	USA	2017	21	M	Renal	No	AIDS	F, oliguria	<i>A. flavus</i>	urine MCS, Histopath, CT, Nuclear medicine	Vori	NS	NS	NS

(Continued)

Table 2. (Continued)

S/N	Author/Year	Country	Year	Age	Sex	Diagnosis	Autopsy	Risk factor	Symptoms	Aetiology	Diagnostics	Antifungal	Surgery	Outcome	Follow-up
19	Zhou <i>et al.</i> ⁴¹	China	2017	46	M	Bladder	No	DM, HTN, liver cirrhosis	F, FP, particles in urine	Asp spp.	Urine MCS, US, histopath	Posa	No	Survived	13 months
20	Patel P <i>et al.</i> ⁴²	India	2017	47	M	Renal	Yes	None	FP, F	Asp spp.	Histopath	None	No	Died	NS
21	Zhou <i>et al.</i> ⁴¹	China	2017	46	M	Renal	No	DM, HTN, liver cirrhosis	Particles in urine	<i>A. fumigatus</i>	Urine MCS	Posa	No	Survived	NS
22	Ullah <i>et al.</i> ⁴³	Pakistan	2016	55	F	Ureter	No	DM, HTN	FP, F, dysuria	Asp spp.	US, CT, Histopath	AMB/Itra	No	Survived	NS
23	Sadagah <i>et al.</i> ⁴⁴	Saudi Arabia	2016	29	M	Renal	No	RTx	Particles in urine	<i>A. fumigatus</i>	Urine MCS, histopath, US	Vori	No	Survived	NS
24	Arous <i>et al.</i> ⁴⁵	Chile	2016	28	M	Renal-R	No	Liver cirrhosis	FP	<i>A. fumigatus</i>	Urine MCS, CT	Vori	No	Survived	36 months
25	Nanjappa <i>et al.</i> ⁴⁶	India	2016	34	M	Renal-B	No	Lithotripsy	Anuria, F	<i>A. flavus</i>	Histopath	AMB/Itra	No	Survived	NS
26	Bulakçı <i>et al.</i> ⁴⁷	Turkey	2016	55	M	Renal	No	Lymphoma, HSCT	Not specified	<i>A. fumigatus</i>	CT, Histopath, US, MRI	NS	Nephrectomy	NS	NS
27	Carlesse <i>et al.</i> ⁴⁸	Brazil	2015	6	M	Renal	No	Burkitt's Lymphoma	Asymptomatic	<i>A. fumigatus</i>	CT, histopath	AMB/Vori	Nephrectomy	Survived	NS
28	Özcan <i>et al.</i> ⁴⁹	Turkey	2015	56	M	Renal	No	DM	Asymptomatic	<i>A. fumigatus</i>	CRP, Histopath, CT	Itra	No	Survived	NS
29	Lee <i>et al.</i> ⁵⁰	Korea	2014	5	F	Renal	No	ALL	F, FP	<i>A. fumigatus</i>	CT, histopath	AMB	No	Survived	24 months
30	Waller <i>et al.</i> ⁵¹	USA	2014	63	M	Renal	No	Liver cirrhosis	F, FP, anorexia, WL	<i>A. fumigatus</i>	Histopath	Vori/Caspo	No	Survived	10 months
31	Shohab <i>et al.</i> ⁵²	Pakistan	2014	2	M	Renal	No	None	F, abd. distension, anuria	<i>A. fumigatus</i>	Urine MCS, US, Histopath	Vori	No	Survived	NS
32	Martínez-Giron <i>et al.</i> ⁵³	Spain	2014	79	M	Bladder	No	DM, RCC	Freq., dysuria, Hx, F	<i>A. niger</i>	US, urine MCS, histopath	Itra	No	Survived	NS
32	Gella <i>et al.</i> ⁵⁴	India	2014	14	M	Renal	No	None	Asymptomatic	<i>A. fumigatus</i>	GM, CT, MCS	Vori	No	Survived	NS
34	Roux <i>et al.</i> ⁵⁵	France	2013	68	M	Prostate and renal	No	CLL, HTN	F, Freq., dysuria	<i>A. fumigatus</i>	Histopath	Vori	No	Survived	8 months
35	Sevic <i>et al.</i> ⁵⁶	Serbia	2013	46	M	Renal-B	Yes	None	F	<i>A. fumigatus</i>	Histopath	NS	No	Died	NS
36	Gupta <i>et al.</i> ⁵⁷	India	2013	56	M	Renal	No	DM	Particles in urine	Asp spp.	NS	NS	No	Survived	NS
				18	M	Renal	Yes	Septicaemia	F, FP	Asp spp.	Imaging	NS	No	Died	NS
				1	M	Renal	Yes	Haemolytic anemia	F	Asp spp.	NS	NS	No	Died	NS
				45	M	Renal-B	No	DM	F, FP, particles in urine	Asp spp.	Imaging	NS	No	Survived	NS
				25	M	Renal	No	RTx	Hx, F	Asp spp.	NS	NS	No	Survived	NS
				40	M	Renal	No	DM	FP, particles in urine	Asp spp.	NS	NS	No	Survived	NS

(Continued)

Table 2. (Continued)

S/N	Author/Year	Country	Year	Age	Sex	Diagnosis	Autopsy	Risk factor	Symptoms	Aetiology	Diagnostics	Antifungal	Surgery	Outcome	Follow-up
37	Siddappa et al. ⁵⁸	India	2012	65	M	Bladder	No	DM, RCC	Hx, nocturia	<i>A. fumigatus</i>	Cystoscopy, urine MCS	None	Radical cystectomy	Survived	NS
38	Sobel et al. ⁵⁹	Germany	2012	67	M	Renal	No	Renal cancer	Hx, Fx, WL	<i>Asp</i> spp.	US, CT, Histopath	Vori	Nephrectomy	Died	1 month
39	Fong et al. ¹⁴	Singapore	2012	47	F	Renal	No	Lymphoma, SLE	Not specified	<i>A. fumigatus</i>	Urine MCS, CT, PET	Vori	No	Survived	NS
40	Melita et al. ⁶⁰	Argentina	2010	38	M	Renal-L	No	AIDS	F, WL, FP	<i>A. fumigatus</i>	Histopath	Vori	Nephrectomy	Survived	12 months
41	Park et al. ⁶¹	Korea	2010	33	M	Renal-B	Yes	HSCT	Headache, FP	<i>Asp</i> spp.	Histopath	AMB/Vori	Nephrectomy	Died	NS
42	Vodovnik et al. ⁶²	UK	2009	53	F	Renal-B	Yes	DM, steroid use	Confusion, vomiting, lethargy	<i>Asp</i> spp.	Autopsy-Histopath	None	No	Died	0.25 months
43	Dervisoglu et al. ⁶³	Turkey	2009	70	M	Bladder	No	DM	Nausea, vomiting	<i>Asp</i> spp.	urine MCS, histopath, US, CT	Caspo	No	Survived	NS
44	Gonzalez-Vicent et al. ⁶⁴	Spain	2008	13	M	Bladder	No	SCD	Dysuria, Hx, FP	<i>A. fumigatus</i>	CT	AMB/Caspo/Posa	No	Survived	8 months
45	Oosten et al. ⁶⁵	Netherlands	2008	37	M	Renal-B	No	AIDS	Hx, FP	<i>A. fumigatus</i>	Histopath, CT, GM, urine MCS	AMB/Vori	No	Survived	NS
46	Haq et al. ⁶⁶	Bangladesh	2007	45	M	Renal	No	DM	FP, particles in urine	<i>A. fumigatus</i>	Urine MCS	AMB/Itra	No	Survived	17 months
47	Meja et al. ¹⁸	Uganda	2005	48	M	Renal -L	No	HIV	FP, F, Vomiting	<i>Asp</i> spp.	Histopath	AMB	Nephrectomy	Survived	12 months
48	Bisi et al. ⁶⁷	Italy	2003	44	M	Renal-L	No	AIDS	FP	<i>A. fumigatus</i>	Urine MCS, US, IVP, CT	AMB	No	Survived	NS
49	Ansari et al. ⁶⁸	India	2001	62	M	Renal-L/Prostate	No	None	FP, F	<i>Aspergillus</i> spp.	Histopath	Itra	No	Died	12 months
50	Kaplan-Pavlovic et al. ⁶⁹	Slovenia	1999	44	M	Prostate	No	CKD	Freq, dysuria	<i>A. flavus</i>	CUG, histopath	AMB/Itra	No	Survived	NS
51	Hemal et al. ⁷	India	1999	62	M	Renal-L/Prostate	No	None	FP, F, WL, dysuria, freq.	<i>Aspergillus</i> spp.	Histopath	Itra	No	Survived	NS
52	de Medeiros et al. ¹⁹	Brazil	1999	49	M	Renal-B	No	Leukaemia	Hx	<i>A. fumigatus</i>	urine MCS, CT	AMB/Itra	No	Died	NS
53	Hadaya et al. ⁸	France	1998	43	M	Renal	No	RTx	Asymptomatic	<i>A. fumigatus</i>	Urine MCS, Histopath	Itra/5FC	Nephrectomy	Survived	NS
54	Krishnamurthy et al. ⁷⁰	India	1998	60	M	Renal	No	None	Anuria	<i>A. fumigatus</i>	Histopath, MCS	AMB/Itra	No	Survived	NS
55	Shirwany et al. ⁷¹	USA	1998	62	M	Prostate	No	RTx	Freq, dysuria	<i>Asp</i> spp.	Histopath	AMB/Itra	No	Survived	NS
56	Sud et al. ⁷²	India	1998	35	NS	Renal-B	No	None	FP, F	<i>Asp</i> spp.	Histopath, GM	AMB	No	Survived	NS
57	Kümmerle et al. ⁷³	Germany	1998	33	NS	Renal-B	No	AIDS/IVD	F	<i>A. fumigatus</i>	CT, Histopath, MCS	AMB/5FC	No	Survived	NS
58	Eisenberg et al. ⁷⁴	USA	1997	44	M	Renal	No	None	FP	<i>Aspergillus</i> spp.	Urine MCS, IVP, Histopath	NS	No	NS	NS
59	Fung et al. ⁷⁵	USA	1997	35	M	Renal	No	AIDS	FP, F, WL	<i>A. fumigatus</i>	Histopath	AMB/Itra	Nephrectomy	Died	18 months

(Continued)

Table 2. (Continued)

S/N	Author/Year	Country	Year	Age	Sex	Diagnosis	Autopsy	Risk factor	Symptoms	Aetiology	Diagnostics	Antifungal	Surgery	Outcome	Follow-up
60	Fiteni et al. ⁹	Spain	1996	29	M	Renal	No	AIDS/IVD	FP, F	<i>A. fumigatus</i>	MCS	AMB/Itra	No	Died	0.5 months
61	Abbas et al. ⁷⁶	USA	1995	65	M	Prostate	No	None	Freu, dysuria	<i>Aspergillus</i> spp.	Histopath	None	Prostatectomy	Survived	NS
62	Martinez-Jabaloyas et al. ⁷⁷	Spain	1995	31	M	Renal-B	No	AIDS/IVD	FP, dysuria, Hx, Fx	<i>A. fumigatus</i>	Urine MCS, US	Itra/Flu/AMB	No	Died	3.5 months
63	Segarra et al. ⁷⁸	Spain	1995	31	M	Renal-R	No	AIDS/IVD	FP, F	<i>A. fumigatus</i>	MCS, Abd US, CT	Itra	No	Died	1 month
64	Godec et al. ⁷⁹	USA	1989	28	F	Renal	No	None	FP	<i>A. fumigatus</i>	Histopath, urine MCS	AMB	No	Survived	NS
65	Khawand et al. ⁸⁰	USA	1989	74	M	Prostate	No	DM	Retention, nocturia	<i>A. flavus</i>	Histopath, MCS	NS	NS	NS	NS
66	Zirinsky et al. ²²	USA	1987	59	M	Renal	No	Pyelonephritis	Hx, F, WL	<i>A. fumigatus</i>	CT scan, MCS	None	Nephrectomy	Survived	NS
67	Raghavan et al. ⁸¹	India	1986	60	M	Renal-B	No	Liver cirrhosis	NS	<i>Asp</i> spp.	Histopath	NS	NS	NS	NS
				27	M	Renal-R	No	Liver cirrhosis	NS	<i>Asp</i> spp.	Histopath	NS	NS	NS	NS
				34	M	Renal-B	No	Liver cirrhosis	NS	<i>Asp</i> spp.	Histopath	NS	NS	NS	NS
				30	M	Renal-L	No	None	NS	<i>Asp</i> spp.	Histopath	NS	NS	NS	NS
				28	M	Renal-B	No	None	Hx	<i>Asp</i> spp.	Histopath	NS	NS	NS	NS
				7	M	Renal-B	No	None	NS	<i>Asp</i> spp.	Histopath	NS	NS	NS	NS
				55	F	Renal-L	No	DM	FL, F, Hx	<i>A. flavus</i>	Urine MCS	None	Nephrectomy	Survived	NS
68	Hartman et al. ²¹	USA	1984	50	M	Renal-R	No	Leukaemia	F, FP	<i>A. fumigatus</i>	Urine MCS, IVP, Cystoscopy, Histopath, CT	AMB	No	Died	NS
69	Lutz et al. ²⁰	France	1984	6	M	Renal	No	Leukaemia	Asymptomatic	<i>Asp</i> spp.	NS	NS	NS	NS	NS
70	Karayannopoulos et al. ²⁴	Greece	1981	50	M	Prostate	No	None	Freq., dysuria	<i>A. flavus</i>	MCS, HISTOPATH	None	Prostatectomy	Survived	NS
71	Flechner et al. ⁸²	USA	1980	46	M	Renal-B	No	DM	FP, dysuria, urgency	<i>A. flavus</i>	Urine MCS, IVP, Cystoscopy, Histopath, CT	AMB/5FC	No	NS	NS
72	Sakamoto et al. ⁸³	Japan	1978	49	M	Bladder	No	Stomach cancer	Dysuria	<i>Asp</i> spp.	CT scan, histopath, urine MCS	AMB	No	Survived	NS
73	Myerson et al. ⁸⁴	USA	1977	6	M	Renal	No	CGD	Not specified	<i>Asp</i> spp.	IVP, histopath	AMB	Nephrectomy	Survived	NS
				52	M	Renal	Yes	Leukaemia	Asymptomatic	<i>Asp</i> spp.	IVP, histopath	NS	No	Died	NS
74	Warshawsky et al. ⁸⁵	USA	1975	22	M	Renal-B	No	DM	FP, Hx	<i>A. fumigatus</i>	Urine MCS, IVP, Histopath	AMB/5FC	Nephrectomy	Survived	NS
75	Chmelv et al. ⁸⁶	USA	1970	20	M	Renal	No	DM, IVD	Asymptomatic	<i>A. fumigatus</i>	Urine MCS, IVP, Cystoscopy	AMB	No	Survived	NS
76	Salgia et al. ⁸⁷	India	1925	48	M	Renal	No	DM	FP, Hx, dysuria	<i>A. glaucus</i>	Urine MCS, histopath	AMB	No	Survived	NS

Abd US, abdominal ultrasound; AIDS, acquired immunodeficiency syndrome; ALL, acute lymphoblastic leukaemia; AMB, Amphotericin B; BDG, Beta-d-Glucan; BPH, Benign Prostatic Hyperplasia; Caspo, Caspofungin; CGD, chronic granulomatous disease; CKD, chronic kidney disease; CLL, chronic lymphocytic leukaemia; CT, computed tomography; DM, Diabetes mellitus; F, Female; Flu, Fluconazole; FP, Flank Pain; GM, Galactomannan; Histopath, histopathology; HSCT, hematopoietic stem cell transplant; HTN, hypertension; Hx, Haematuria; Itra, Itraconazole; IVD, intravenous drug use; LTx, Liver transplantation; M, Male; MCS, microscopy, culture and sensitivity; NS, not specified; PET, Positron emission tomography; Renal - B, both kidneys.; Renal - L, left kidney; Renal - R, Right kidney; RCC, renal cell carcinoma; RTx, renal transplantation; SCD, sickle cell disease; SLE, systemic lupus erythematosus; US, ultrasound; Vori, Voriconazole; WL, weight loss.

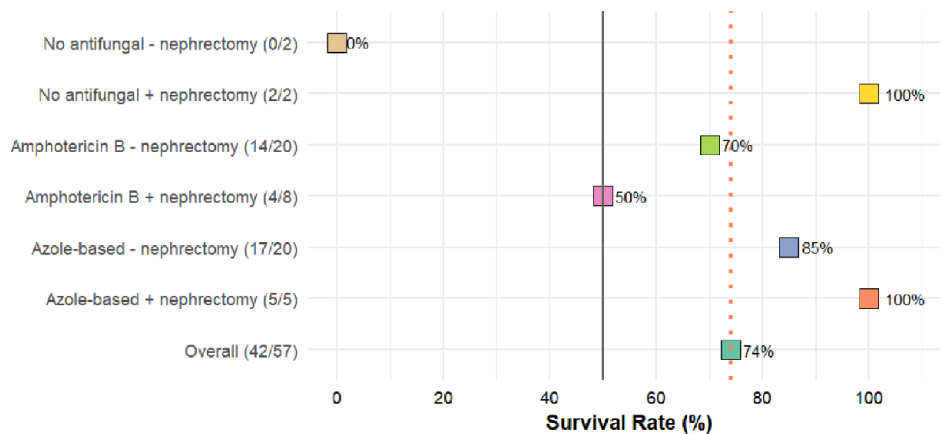


Figure 3. Survival rates in renal aspergillosis stratified by antifungal therapy and nephrectomy status.

Among the 36 cases with both antifungal treatment and survival status available, the comparison of mortality rates across different antifungal treatment regimens revealed proportions of deaths as follows: 25% (4/16) for patients on amphotericin B, 40% (2/5) for patients with amphotericin B in combination with voriconazole, and 6.7% (1/15) for patients on voriconazole alone or in combination with itraconazole ($p=0.74$).

In the group of 66 cases with both nephrectomy and survival status available, there was no significant difference in mortality rates between those who underwent nephrectomy (4/15, 26.7%) and those who did not (15/51, 29.4%) ($p=0.8$).

For 57 cases of renal aspergillosis with antifungal, nephrectomy and mortality status stated, overall survival was 74%, and survival was relatively higher among cases treated with azole-based regimens with or without nephrectomy (85% and 100%), compared to those treated with amphotericin B – based regimens with or without nephrectomy (50% and 70%). However, the difference in mortality was not statistically significant ($p=0.49$), and could reflect other advances in medicine, Figure 3.

Discussion

Renal aspergillosis (nephromycosis aspergillina) was first described by Dr Ross in 1891.⁸⁸ Renal and genito-urinary aspergillosis are uncommon conditions, characterized by an unclear optimal treatment regimen and prognosis.^{29,41} This comprehensive systematic review offers valuable

insights into various aspects of this relatively rare condition. Isolated renal cases constituted the majority (81.3%) of the cases included in this study, with diabetes mellitus, HIV, and hepatic cirrhosis emerging as the most significant underlying conditions. Most of these patients were immunocompromised and thus at high risk for invasive disease, mortality, and poor responsiveness to treatment. Therefore, clinicians should remain vigilant for early detection and consider tailored treatment approaches for individuals with these risk factors, given that clinical symptoms of renal and genitourinary aspergillosis, such as flank pain, fever, and lower urinary tract symptoms, are non-specific. Among patients with renal aspergillosis, mortality was unacceptably high at 28%. Further research is warranted to establish standardized treatment regimens and explore innovative therapeutic strategies to improve patient outcomes in this challenging clinical context.

We observed a distinct male predominance, with over 85% of the identified cases of renal aspergillosis being males. Whereas this association has not previously studied, we speculate that certain risk factors might be more prevalent among males, like occupational and behavioural exposures that make males more susceptible. As seen in this study, a higher proportion of men had diabetes mellitus, HIV/AIDS, and liver cirrhosis as the underlying comorbidities. Besides invasive candidiasis, this finding is consistent with previous studies of other invasive fungal infections, including pulmonary aspergillosis.^{26,89–91} Consequently, male sex has also been shown to be significantly associated with mortality,

although this was not significant in our study. Besides underlying comorbidities and behavioural risk factors, there may exist the role of genetics and gender-specific immunological differences that may render males more susceptible, which necessitates further research studies into the mechanisms.

We found *A. fumigatus* as the most frequent *Aspergillus* species implicated in nearly 42.9% of all cases. Historically, *A. fumigatus* has been recognized as the primary pathogen in the *Aspergillus* genus, given its ability to thrive in a wide range of environmental conditions and its enhanced virulence factors. It is also the leading cause of invasive aspergillosis, including pulmonary aspergillosis. Its predominance in renal aspergillosis could be attributed to the mode of spread, which is believed to be primarily haematogenous. Renal and urinary tract aspergillosis is particularly concerning, as *A. fumigatus* infections often pose therapeutic challenges due to antifungal resistance and aggressive disease manifestation.^{92–94} While other species such as *A. flavus* and *A. niger* were also implicated in our study, the pronounced prevalence of *A. fumigatus* necessitates an increased focus on developing targeted diagnostic tools, therapeutic strategies, and public health measures for its effective management. Continued research into its pathogenicity, interactions with the human host, and resistance patterns will be pivotal for advancing our understanding and combating this pathogen.

Clinically apparent renal aspergillosis is a localized form of invasive aspergillosis, which particularly occurs in patients with systemic immunosuppression as seen in this review. If renal aspergillosis is a component of disseminated aspergillosis and is clinically silent, renal parenchymal disease can be treated effectively using modern antifungal therapy. However, if treatment of disseminated aspergillosis is successful, renal disease in this context does need to be addressed separately. Aspergillosis occurring in HIV/AIDS has recently been reviewed.⁹⁵ Histopathology, biomarkers, and medical imaging are key in the diagnosis of invasive aspergillosis.⁹⁶ In our review, we found that histopathology was the primary diagnostic method in over 70% of the cases.

Histopathology, biomarkers, and medical imaging are key in the diagnosis of invasive aspergillosis.⁹⁶ In our review, we found that histopathology was the primary diagnostic method in over 70% of the

cases. The few reports of cases of renal aspergillosis in Africa, which has a high burden of risk factors for renal and invasive aspergillosis such as HIV, DM and increasing cancer burden is probably due to limited access and availability of diagnostics. In our recent diagnostic survey of access to World Health Organization-recommended essential diagnostics, we found that significant gaps exist in the accessibility of vital diagnostic tools for invasive fungal infections in Africa, specifically concerning *Aspergillus* antigen testing and contemporary medical imaging methods such as CT and MRI.⁹⁷ While concrete data on galactomannan (GM) in renal aspergillosis remains elusive, there is some insight when renal involvement is part of disseminated invasive aspergillosis. In such cases, a slightly elevated GM positivity rate compared to invasive pulmonary aspergillosis may be anticipated, contingent on factors like prophylaxis and neutropenia.⁹⁸ In isolated renal aspergillosis, the likelihood of serum positivity is expected to be minimal. However, there is potential for urinary GM to yield positive results. Notably, a novel urinary GM assay has shown promise, often yielding positive results due to vesicles present in the urine.⁹⁹

Managing renal and genitourinary aspergillosis presents significant challenges. Treating renal parenchymal disease necessitates systemic antifungal therapy, including options such as amphotericin B, systemic triazoles, or echinocandins, singly or in combination, although the effectiveness of these antifungal agents remains unproven. Co-administering flucytosine might be beneficial due to its substantial urinary excretion and synergistic effects with amphotericin B;²³ however, its activity is only demonstrable at acid pH, with uncertain implications for activity in the urine.¹⁰⁰

Expert opinion suggests a combination of medical and surgical approaches, involving topical and systemic antifungal agents, endourological procedures for cleansing and reducing mass, and potentially nephrectomy, depending on individual factors. Unfortunately, nephrectomy is often necessary, which is a less favourable option for patients with bilateral disease. We did not observe any difference in mortality rates for both patients on amphotericin B-based or triazole-based regimens, with or without nephrectomy. However, patients who received triazoles voriconazole, with nephrectomy had excellent survival. This is in line with current treatment guidelines that favour the use of voriconazole over amphotericin B for the management of invasive aspergillosis. All patients

with prostatic aspergillosis in the review survived, and a combined medical and surgical strategy has been recommended.

The infectious diseases society of America guidelines for the treatment of aspergillosis propose a comprehensive approach, advocating both medical and urologic strategies for renal aspergillosis.¹⁰¹ For ureteral obstruction, the recommendation is decompression if feasible, coupled with the local instillation of amphotericin B deoxycholate through a nephrostomy tube. For parenchymal disease, voriconazole is the preferred treatment. The guideline recommends medical management for smaller abscesses and surgical drainage for larger abscesses, with microwave ablation showing promise as a supplementary therapy in select cases where surgery is a less viable option. Nephrectomy is only recommended as a last resort when medical therapy has failed.

Strengths and limitations

The strength of our study lies in its comprehensive analysis of isolated renal and genito-urinary aspergillosis cases across diverse publications, contributing to a robust understanding of this rare condition. Moreover, to the best of our knowledge, this is the first systematic review to synthesize such comprehensive literature on genito-urinary aspergillosis. However, the scarcity of available cases and the inherent limitations of case reports and case series may impact the generalizability of our findings. Furthermore, the potential for publication bias cannot be disregarded, as positive outcomes may be more likely to be reported. Due to the heterogeneity of the studies and the type of data available, no meta-analysis was performed. As a result, the study did not provide pooled effect sizes, which might limit the depth of the conclusions.

Implications

Our findings underscore the need for heightened clinical awareness among healthcare professionals, particularly in populations with established risk factors, such as diabetes mellitus, which could lead to earlier detection and intervention. The recognition of varying *Aspergillus* species emphasizes the importance of tailored treatment strategies based on local epidemiology. Additionally, our study highlights the need for further research to refine diagnostic protocols and optimize treatment approaches, especially con-

sidering the mortality rate and potential disparities in patient outcomes.

Conclusion

In summary, all-cause mortality in patients with renal aspergillosis was 28% and all patients with bladder, prostate or ureteric aspergillosis survived. DM, HIV, and other immunosuppressive conditions were common among these cases. While varied treatment strategies were observed, mortality rates showed no significant differences based on treatments or nephrectomy status. Further research is needed to refine diagnostics, optimize treatments, and enhance awareness among clinicians for early detection and management.

Declarations

Ethics approval and consent to participate
Not applicable.

Consent for publication
Not applicable.

Author contributions

Felix Bongomin: Conceptualization; Data curation; Formal analysis; Funding acquisition; Investigation; Methodology; Project administration; Resources; Software; Supervision; Validation; Visualization; Writing – original draft; Writing – review & editing.

Bethan Morgan: Data curation; Methodology; Resources; Software; Writing – original draft; Writing – review & editing.

Bassey E. Ekeng: Data curation; Formal analysis; Methodology; Validation; Visualization; Writing – original draft; Writing – review & editing.

Martha F. Mushi: Data curation; Formal analysis; Investigation; Methodology; Writing – original draft; Writing – review & editing.

Winnie Kibone: Data curation; Investigation; Methodology; Project administration; Writing – original draft; Writing – review & editing.

Ronald Olum: Visualization; Writing – original draft; Writing – review & editing.

David B. Meya: Conceptualization; Data curation; Formal analysis; Investigation; Methodology; Validation; Visualization; Writing – original draft; Writing – review & editing.

Davidson H. Hamer: Conceptualization; Data curation; Formal analysis; Funding acquisition; Investigation; Methodology; Resources; Supervision; Validation; Visualization; Writing – original draft; Writing – review & editing.

David W. Denning: Conceptualization; Data curation; Formal analysis; Funding acquisition; Investigation; Methodology; Project administration; Resources; Supervision; Validation; Visualization; Writing – original draft; Writing – review & editing.

Acknowledgements

None.

Funding

The authors disclosed receipt of the following financial support for the research, authorship, and/or publication of this article: This work was supported by the Carigest SA Conny Naeva Charitable Foundation as part of the ‘Chronic Pulmonary Aspergillosis: Optimization of Therapy, Immunogenetic Screening, and Diagnosis in Uganda [CPA_OPTIONS_Uganda]’ PhD studentship award to Dr Felix Bongomin at the University of Manchester, United Kingdom. CARIGEST SA did not play any role in the design, implementation, and analysis of the study.

Research reported in this publication was supported by the Fogarty International Center of the National Institutes of Health under Award Number D43 TW010543. The content is solely the responsibility of the authors and does not necessarily represent the official views of the National Institutes of Health.

Competing interests

The authors declare that there is no conflict of interest.

Availability of data and materials

All underlying data have been included in the manuscript.

ORCID iD

Felix Bongomin  <https://orcid.org/0000-0003-4515-8517>

References

1. Cadena J, Thompson GR and Patterson TF. Invasive Aspergillosis: current strategies for

diagnosis and management. *Infect Dis Clin North Am* 2016; 30: 125–142.

2. Latgé JP and Chamilos G. Aspergillus fumigatus and aspergillosis in 2019. *Clin Microbiol Rev* 2020; 33: 1–75.
3. Duthie R and Denning DW. Aspergillus fungemia: report of two cases and review. *Clin Infect Dis* 1995; 20: 598–605.
4. Lortholary O, Guillemin L and Dupont B. [Extra-pulmonary manifestations of invasive aspergillosis]. *Ann Med Interne (Paris)* 1995; 146: 96–101.
5. Hori A, Kami M, Kishi Y, *et al.* Clinical significance of extra-pulmonary involvement of invasive aspergillosis: a retrospective autopsy-based study of 107 patients. *J Hosp Infect* 2002; 50: 175–182.
6. Wise GJ and Silver DA. Fungal infections of the genitourinary system. *J Urol* 1993; 149: 1377–1388.
7. Hemal AK, Talwar M and Dinda A. Concomitant renal and prostatic aspergillosis. *Int Urol Nephrol* 1999; 31: 157–162.
8. Hadaya K, Akposso K, Costa de Beauregard MA, *et al.* Isolated urinary aspergillosis in a renal transplant recipient. *Nephrol Dial Transplant* 1998; 13: 2382–2384.
9. Fiteni I, Crusells MJ, Cuesta J, *et al.* Renal invasive aspergilloma: unusual infection in AIDS. *J Infect* 1996; 33: 61–63.
10. Wise GJ. Aspergillosis of prostate. *Urology* 1990; 35: 98.
11. Antinori S, Ridolfo AL, Fasan M, *et al.* AIDS-associated cryptococcosis: a comparison of epidemiology, clinical features and outcome in the pre- and post-HAART eras. Experience of a single centre in Italy. *HIV Med* 2009; 10: 6–11.
12. Desoubreux G and Cray C. Animal models of aspergillosis. *Comp Med* 2018; 68: 109–123.
13. Denning DW and Stevens DA. Efficacy of cilofungin alone and in combination with amphotericin B in a murine model of disseminated aspergillosis. *Antimicrob Agents Chemother* 1991; 35: 1329–1333.
14. Fong W and Chua YY. Primary aspergillosis of the kidney in systemic lupus erythematosus and positron emission tomography-computed tomography. *Int J Rheum Dis* 2019; 22: 742–745.
15. Maquera-Afaray J, Luna-Vilchez M, Portillo-Alvarez D, *et al.* Primary renal aspergillosis in a newborn: a case report and review of the

- literature on children. *Turk J Pediatr* 2022; 64: 580–584.
16. Davies SP, Webb WJS, Patou G, *et al.* Renal aspergilloma—a case illustrating the problems of medical therapy. *Nephrol Dial Transplant* 1987; 2: 568–572.
 17. Das S, More AR and Iyadurai R. Bilateral renal aspergillosis in an immunocompetent host. *J Fam Med Prim Care* 2017; 6: 873–875.
 18. Meya D, Lwanga I, Ronald A, *et al.* A renal aspergilloma—an unusual presentation of aspergillosis in an HIV patient. *Afr Health Sci* 2005; 5: 341–342.
 19. de Medeiros CR, Dantas da Cunha A, Pasquini R, *et al.* Primary renal aspergillosis: extremely uncommon presentation in patients treated with bone marrow transplantation. *Bone Marrow Transplant* 1999; 24: 113–114.
 20. Lutz P, Boulate P, Seiller F, *et al.* [Isolated renal aspergillosis in a leukemic boy]. *Pediatrie* 1984; 39: 669–673.
 21. Hartman BJ, Coleman M, Brause BD, *et al.* Localized renal aspergillosis with hairy cell leukemia: a review of urinary tract aspergillosis in malignant and nonmalignant conditions. *Cancer Invest* 1984; 2: 199–202.
 22. Zirinsky K, Auh YH, Hartman BJ, *et al.* Computed tomography of renal aspergillosis. *J Comput Assist Tomogr* 1987; 11: 177–178.
 23. Felton T, Troke PF and Hope WW. Tissue penetration of antifungal agents. *Clin Microbiol Rev* 2014; 27: 68–88.
 24. Karayannopoulos SI and Stylianea A. Aspergillus flavus in prostatic fluid. *Br J Urol* 1981; 53: 192.
 25. Kone K, Nagaraj P, Mallikarjun NT, *et al.* Identifying silent fungal infections complicating obstructive uropathy due to renal papillary necrosis in diabetic patients—a step towards preventing recurrent obstructive uropathy. *J Endoluminal Endourol* 2021; 4: e36–e44.
 26. Sharmin F. Urinary tract aspergillosis in a patient with diabetes who underwent total abdominal hysterectomy. *Bangladesh J Obstet Gynecol* 2020; 33: 74–77.
 27. Shamseer L, Moher D, Clarke M, *et al.* Preferred reporting items for systematic review and meta-analysis protocols (PRISMA-P) 2015: elaboration and explanation. *BMJ* 2015; 349: g7647–g7647.
 28. Wan ER, Elands SA and Walsh SB. Post-transplantation cutaneous and renal Aspergillus infection. *Int J Infect Dis* 2023; 127: 23–25.
 29. Tosh JM, Navriya SC, Agrawal S, *et al.* Bilateral renal aspergillosis with a fungal cast masquerading as renal malignancy. *BMJ Case Rep* 2023; 16: e249834.
 30. Paul S, Singh V, Sankhwar S, *et al.* Renal aspergillosis secondary to renal instrumentation in immunocompetent patient. *BMJ Case Rep* 2013; 2013: bcr2013200306.
 31. Martínez-Salas A de J, Aquino-Matus JE, López-Vejar CE, *et al.* Localized genitourinary tract Aspergillus infection in an immunocompetent patient: bladder and epididymal aspergillosis. *Urol Case Reports* 2022; 42: 102012.
 32. Toledo MG, Alves HR, Cambuzzi I, *et al.* Urinary Aspergillosis in a patient with systemic lupus erythematosus (SLE). *Case Rep Infect Dis* 2023; 2023: 5575300.
 33. Mahdavi M, Mortaz-Hejri G, Shahzadi H, *et al.* Case of renal aspergillosis after heart transplant: diagnosis and treatment. *Int J Organ Transplant Med* 2021; 12: 50–52.
 34. Khilar N, Gupta N, Adhikari P, *et al.* Xanthogranulomatous pyelonephritis due to Aspergillus in a non-diabetic older patient. *BMJ Case Rep* 2021; 14: e245067.
 35. Karaisz F, Upadhyay N, Xie C, *et al.* Aspergillus fumigatus vertebral osteomyelitis with intracardiac and renal aspergillomas in a liver transplant recipient: a clinical vignette. *Am J Gastroenterol* 2020; 115: S1322.
 36. Flores-Lovon K, Lozano N, Cuba N, *et al.* Renal aspergillosis in a patient with acquired immunodeficiency syndrome. *Urol Sci* 2020; 31: 238–240.
 37. Altinkaynak M, Kalayoglu Besisik S and Tascioglu C. Late renal aspergilloma after autologous stem cell transplantation mimicking secondary malignancy. *Leuk Res* 2019; 85: S64.
 38. Smolovic B, Vukcevic B, Muhovic D, *et al.* Renal aspergillosis in a liver transplant patient: a case report and review of literature. *World J Clin Cases* 2018; 6: 1155–1159.
 39. Nagvekar V, Pranatharthi CH, Gopalakrishnan R, *et al.* Fatal aspergillosis of the renal vasculature in a combined liver-kidney transplant recipient. *Indian J Med Microbiol* 2018; 36: 444–446.
 40. Kamal M, Apewokin S, Anand M, *et al.* Late-onset allograft aspergillosis in an HIV-positive renal transplant recipient: a case report. *Transplant Proc* 2017; 49: 1570–1573.
 41. Zhou L, Zhao H, Chen Z, *et al.* Urinary tract aspergillosis in a patient with chronic kidney disease. *BMJ Case Rep* 2017; 2017: bcr2017221638.
 42. Patel P, Shah S, Shukla K, Kumar R, *et al.* Fungal Pyelonephritis due to Aspergillus: a case

- report. *Indian J Urol* 2017; 33: 1–6. <https://doi.org/10.1089/end.2016.29020.abstracts>.
43. Ullah SR, Jamshaid A and Zaidi SZ. Renal aspergilloma presenting with pelvi-ureteric junction Obstruction (PUJO). *J Pak Med Assoc* 2016; 66: 903–904.
 44. Sadagah L, Alharbi M, Alshomrani M, *et al.* Renal allograft aspergillus infection presenting with obstructive uropathy: a case report. *Transplant Proc* 2017; 49: 193–197.
 45. Esteban A-B, and Moll-Manzur C. Aspergilosis Renal Posterior a Trasplante Hepático: Informe de Un Caso Infrecuente. *Gastroenterol Hepatol* 2018; 41: 30–31.
 46. Nanjappa B, Gupta SS, Appannanavar S, *et al.* A rare cause of Anuria: Bilateral Renal Fungal balls in an adult male. *Journal of Endourol* 2016; 30: P1-A464.
 47. Bulakçı M, Kartal MG, Çelenk E, *et al.* Multimodality imaging findings of a renal Aspergilloma. *Balkan Med J* 2016; 33: 701–705.
 48. Carlesse F, Marcos ACC, Seber A, *et al.* Renal aspergillosis in a 6-year-old male with Burkitt’s lymphoma. *Pediatr Infect Dis J* 2015; 34: 679–680.
 49. Ozcan C, Yilmaz G, Suer E, *et al.* A case of renal aspergillosis mimicking renal cell cancer. *Klimik Derg* 2015; 28: 42–44.
 50. Lee JH, Im SA and Cho B. Renal infarction secondary to invasive aspergillosis in a 5-year-old girl with acute lymphoblastic leukemia. *J Pediatr Hematol Oncol* 2014; 36: 296.
 51. Waller S, Raglow Z, Lemons S, *et al.* Microwave ablation of a large renal aspergilloma. *Transpl Infect Dis* 2014; 16: 496–500.
 52. Shohab D, Hussain I, Khawaja A, *et al.* Primary renal aspergillosis and xanthogranulomatous pyelonephritis in an immuno-competent toddler. *J Coll Physicians Surg* 2014; 24(Suppl. 2): 101.
 53. Martínez-Girón R, Martínez-Torre S and Mosquera-Martínez J. Bladder aspergillosis detected by urine cytology. *Diagn Cytopathol* 2015; 43: 403–406.
 54. Gella V, Upendra S and Barwad A. An unusual cause of lung and kidney mass. *Chest* 2014; 145.
 55. Roux C, Thyss A and Gari-Toussaint M. Prostatic and renal aspergillosis due to *Aspergillus fumigatus* in a patient receiving alemtuzumab for chronic lymphocytic leukaemia. *J Mycol Med* 2013; 23: 270–273.
 56. Joveš Sević B, Stojanović M, Obradović D, *et al.* When pulmonary nodules, epistaxis and renal lesion do not add up to Wegener’s granulomatosis? *Med Glas* 2013; 10: 400–402.
 57. Gupta KL, Muthukumar T, Joshi K, *et al.* Papillary necrosis with invasive fungal infections: a case series of 29 patients. *Clin Kidney J* 2013; 6: 390–394.
 58. Siddappa S, Mythri KM, Kowsalya R, *et al.* An unusual case of non-disseminated bladder aspergillosis in a setting of transitional cell carcinoma. *Indian J Med Microbiol* 2012; 30: 106–108.
 59. Sobel C, Franzaring I, Pullwitt J, *et al.* [Renal aspergilloma: first manifestation of an occult sarcomatoid carcinoma]. *Urologe A* 2012; 51: 1444–1446.
 60. Metta H, Corti M, Redini L, *et al.* Renal abscess due to *Aspergillus fumigatus* as the only sign of disseminated aspergillosis in a patient with AIDS. *Rev Iberoam Micol* 2010; 27: 136–139.
 61. Park H, Lee MJ, Kim Y, *et al.* Primary renal aspergillosis and renal stones in both kidneys associated with hematopoietic stem cell transplant. *Korean J Hematol* 2010; 45: 275–278.
 62. Vodovnik A. Isolated diffuse invasive renal aspergillosis in an immunocompromized patient due to longstanding steroid treatment: a case report. *Cases J* 2009; 2: 6825.
 63. Dervisoglu E, Dikmen E, Filinte D, *et al.* Isolated bladder aspergillosis as the primary presentation of non-oliguric acute renal failure. *Scand J Urol Nephrol* 2008; 42: 189–191.
 64. González-Vicent M, Lassaletta A, López-Pino MA, *et al.* *Aspergillus* “fungus ball” of the bladder after hematopoietic transplantation in a pediatric patient: successful treatment with intravesical voriconazole and surgery. *Pediatr Transplant* 2008; 12: 242–245.
 65. Oosten AW, Sprenger HG, van Leeuwen JTM, *et al.* Bilateral renal aspergillosis in a patient with AIDS: a case report and review of reported cases. *AIDS Patient Care STDS* 2008; 22: 1–6.
 66. Haq JA, Khan MA, Afroze N, *et al.* Localized primary renal aspergillosis in a diabetic patient following lithotripsy—a case report. *BMC Infect Dis* 2007; 7: 58.
 67. Bisi M, Palou J, Segarra J, *et al.* [Percutaneous treatment of a primary renal aspergilloma in a patient with AIDS]. *Arch Ital Di Urol* 2003; 75: 119–123.

68. Ansari MS, Nabi G, Singh I, *et al.* Mycotic abdominal aortic aneurysm: a fatal sequel to concomitant prostatic and renal aspergillosis. Case report and review of the literature. *Urol Int* 2001; 66: 36–37.
69. Kaplan-Pavlovic S, Masera A, Ovcak Z, *et al.* Prostatic aspergillosis in a renal transplant recipient. *Nephrol Dial Transplant* 1999; 14: 1778–1780.
70. Krishnamurthy R, Aparajitha C, Abraham G, *et al.* Renal aspergillosis giving rise to obstructive uropathy and recurrent anuric renal failure. *Geriatr Nephrol Urol* 1998; 8: 137–139.
71. Shirwany A, Sargent SJ, Dmochowski RR, *et al.* Urinary tract aspergillosis in a renal transplant recipient. *Clin Infect Dis* 1998; 27: 1336.
72. Sud K, D’Cruz S, Kohli HS, *et al.* Isolated bilateral renal aspergillosis: an unusual presentation in an immunocompetent host. *Ren Fail* 1998; 20: 839–843.
73. Kümmerle S and Wedler H. Renal abscesses in an AIDS patient caused by *Aspergillus fumigatus*. *Urol Int* 1998; 61: 52–54.
74. Eisenberg RL, Hedgcock MW and Shanser JD. *Aspergillus* mycetoma of the renal pelvis associated with ureteropelvic junction obstruction. *J Urol* 1977; 118: 466–467.
75. Fung Y and Yeh HC. Renal aspergilloma mimicking a tumor on ultrasonography. *J Ultrasound Med* 1997; 16: 555–557.
76. Abbas F, Kamal MK and Talati J. Prostatic aspergillosis. *J Urol* 1995; 153: 748–750.
77. Martinez-Jabaloyas J, Osca JM, Ruiz JL, *et al.* Renal aspergillosis and AIDS. *Eur Urol* 1995; 27: 167–169.
78. Segarra J, Chéchile G and Sole Balcells F. Renal abscess due to *Aspergillus fumigatus* in a patient with the acquired immunodeficiency syndrome. *Urol Int* 1995; 55: 60–62.
79. Godec CJ, Mielnick A and Hilfer J. Primary renal aspergillosis. *Urology* 1989; 34: 152–154.
80. Khawand N, Jones G and Edson M. Aspergillosis of prostate. *Urology* 1989; 34: 100–101.
81. Raghavan R, Date A and Bhaktaviziam A. Fungal and nocardial infections of the kidney. *Histopathology* 1987; 11: 9–20.
82. Flechner SM and McAninch JW. Aspergillosis of the urinary tract: ascending route of infection and evolving patterns of disease. *J Urol* 1981; 125: 598–601.
83. Sakamoto S, Ogata J, Sakazaki Y, *et al.* Fungus ball formation of *aspergillus* in the bladder. an unusual case report. *Eur Urol* 1978; 4: 388–389.
84. Myerson DA and Rosenfield AT. Renal aspergillosis: a report of two cases. *J Can Assoc Radiol* 1977; 28: 214–216.
85. Warshawsky AB, Keiller D and Gittes RF. Bilateral renal aspergillosis. *J Urol* 1975; 113: 8–11.
86. Chmel H and Grieco MH. Cerebral mucormycosis and renal aspergillosis in heroin addicts without endocarditis. *Am J Med Sci* 1973; 266: 225–231.
87. Salgia P and Mani MK. Renal aspergillosis - Case report. *Nephron* 1985; 40: 376–378.
88. Ross. *Nephromycosis aspergillina in Vorlaufige Mittheilung uber eineige falle von mycosis in menschen.* 1891, pp. 504–506.
89. Apostolopoulou A, Esquer Garrigos Z, Vijayvargiya P, *et al.* Invasive pulmonary Aspergillosis in patients with SARS-CoV-2 infection: a systematic review of the literature. *Diagnostics* 2020; 10: 807.
90. Bongomin F, Ekeng BE, Kibone W, *et al.* Invasive fungal diseases in Africa: a critical literature review. *J Fungi* 2022; 8: 1236.
91. Egger M, Hoenigl M, Thompson GR, *et al.* Let’s talk about sex characteristics—As a risk factor for invasive fungal diseases. *Mycoses* 2022; 65: 599–612.
92. Chowdhary A, Sharma C, Hagen F, *et al.* Exploring azole antifungal drug resistance in *Aspergillus fumigatus* with special reference to resistance mechanisms. *Future Microbiol* 2014; 9: 697–711.
93. Shishodia SK, Tiwari S and Shankar J. Resistance mechanism and proteins in *Aspergillus* species against antifungal agents. *Mycology* 2019; 10: 151–165.
94. Guegan H, Prat E, Robert-Gangneux F, *et al.* Azole resistance in *Aspergillus fumigatus*: a five-year follow up experience in a tertiary hospital with a special focus on cystic fibrosis. *Front Cell Infect Microbiol* 2021; 10.
95. Denning DW and Morgan EF. Quantifying deaths from Aspergillosis in HIV positive people. *J Fungi* 2022; 8: 1131.
96. Peter Donnelly J, Chen SC, Kauffman CA, *et al.* Revision and update of the consensus definitions of invasive fungal disease from the european organization for research and treatment of cancer and the mycoses study group education and research consortium. *Clin Infect Dis* 2020; 71: 1367–1376.

97. Tufa TB, Bongomin F, Fatallah A, *et al.* Access to the World Health Organization-recommended essential diagnostics for invasive fungal infections in critical care and cancer patients in Africa: a diagnostic survey. *J Infect Public Health* 2023; 16: 1666–1674.
98. Denning DW. Invasive Aspergillosis. *Clin Infect Dis* 1998; 26: 781–803.
99. Pearl Diagnostics. *MycosELATM Aspergillus assay*. Pearl Diagnostics, Mumbai, India, 2023.
100. Gsaller F, Furukawa T, Carr PD, *et al.* Mechanistic basis of pH-dependent 5-flucytosine resistance in *Aspergillus fumigatus*. *Antimicrob Agents Chemother* 2018; 62: e02593-17.
101. Patterson TF, Iii RT, Denning DW, *et al.* Practice guidelines for the diagnosis and management of aspergillosis: 2016 update by the infectious diseases society of America. *Clin Infect Dis* 2016; 63: 1–60.

Visit Sage journals online
[journals.sagepub.com/
home/tau](https://journals.sagepub.com/home/tau)

 Sage journals